

Intranasal disulfiram-induced encephalopathy: clinical and neuroimage finding

Ana Matas-García, Adrián Téllez, Sara Fernández, Emilio Salgado, Pedro Castro

Introduction. Disulfiram-induced-encephalopathy is a rare complication that has been well described in adults. Although it usually occurs in acute intoxication with high doses of disulfiram, late onset encephalopathy has also been reported. Some authors propose the inhibition of dopamine beta-hydroxylase mediated by toxic metabolites of disulfiram as the main responsible, but the exact mechanism remains unclear. The aim of this report was to describe the clinical and neuroimaging findings in an unusual case of acute encephalitis due to disulfiram toxicity associated to chronic intranasal consume.

Case report. A chronic alcoholic who referred snorted use of a very high dose of disulfiram without simultaneous alcohol intake developed an acute encephalopathy with a rapidly progressive respiratory failure. A characteristic neuroimage finding consisting in extensive bilateral symmetric involvement of both pallidal *nuclei* was described. Recovery and neurologic improvement were slow. Two months after the intoxication, the patient still had slight intentional tremor and a scheduled magnetic resonance imaging. showed evolution of symmetrical areas of cytotoxic edema to necrosis.

Conclusion. Disulfiram-induced neurotoxicity must be suspect during chronic therapy with disulfiram or after acute ingestion of high doses. Symptoms such as symmetric sensory and motor neuropathy, confusion, catatonia, parkinsonism, ataxia, choreoathetosis, seizures and encephalopathy should make us rule out this disorder. A brain imaging test should be performed in these patients since a characteristic involvement of both *nuclei pallidus* has been described, but it is not present in all patients.

Key words. Alcoholism. Disulfiram. Encephalopathy. Intoxication. Neurotoxicity. *Nuclei pallidus* infarction.

Introduction

Disulfiram-induced encephalopathy is a rare complication that has been well described in adults. Although it usually occurs in acute intoxication with high doses of disulfiram, late onset encephalopathy has also been reported. Some authors propose the inhibition of dopamine beta-hydroxylase mediated by toxic metabolites of disulfiram as the main responsible, but the exact mechanism remains unclear [1-4]. The aim of this report was to describe the clinical and neuroimaging findings in an unusual case of acute encephalitis due to disulfiram toxicity associated to chronic intranasal consume.

Case report

A 48-years old male was transferred to our hospital from a psychiatric center with a three day history of drowsiness, cerebellar ataxia and dysarthric speech. He denied fever in the preceding month. He re-

ferred snorted use of escitalopram and clonazepam on the previous days as well as consumption of intranasal disulfiram (1-2 g per day with a maximum dose of 10 g per day two days ago) during the last two months intended for recreational purposes.

He had a past medical history of hypertension without treatment and paranoid schizophrenia that had led to three admissions due to acute crisis associated to treatment discontinuation. He was on olanzapine 10 mg/8 horas and paliperidone 100 mg intramuscular monthly for the schizophrenia, as well as clonazepam 0.5 mg/24 hours and escitalopram 15 mg/24 hours. He was also under treatment with disulfiram 250 mg per day orally for chronic alcoholism despite still having an active consumption pattern.

On examination at the emergency department, respiratory rate was 20 breaths/minute, oxygen saturation was 98% to room air, heart rate was 85 beats/minute, blood pressure was 177/100 mmHg and the temperature was 36.2 °C. The patient was stuporous and disoriented with a Glasgow coma

Medical Intensive Care Unit (A. Matas-García, A. Téllez, S. Fernández, P. Castro). Medical Toxicology Unit. Emergency Department. Hospital Clínic. Barcelona, Spain (E. Salgado).

Corresponding author:

Dr. Ana Matas García. Hospital Clínic. Carrer de Villarroel, 170. E-08036 Barcelona.

E-mail:

anmatas@clinic.cat

Accepted:

14.10.22.

Conflict of interests:

The authors declare no conflicts of interest.

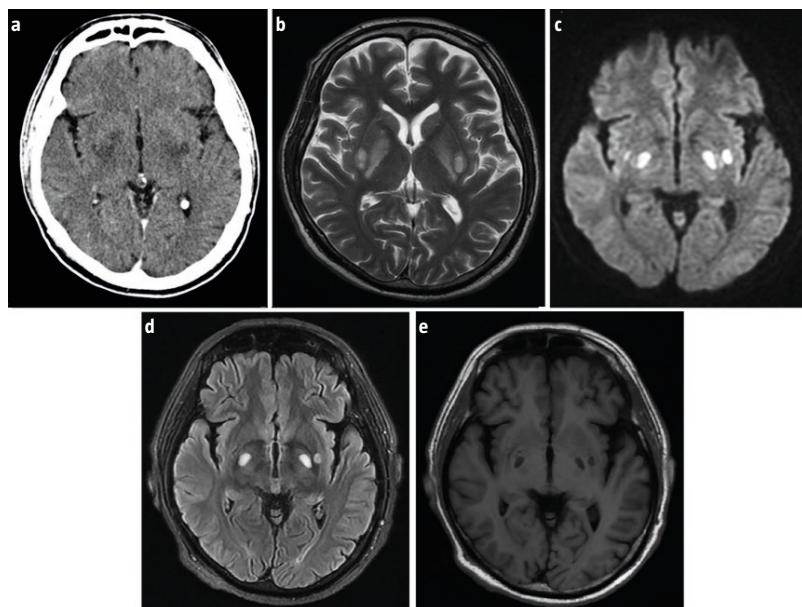
How to cite this article:

Matas-García A, Téllez A, Fernández S, Salgado E, Castro P. Intranasal disulfiram- induced encephalopathy: clinical and neuroimage findings. Rev Neurol 2022; 75: 357-60. doi: 10.33588/rn.7511.2021415.

[Versión española disponible en www.neurologia.com](https://www.neurologia.com)

© 2022 Revista de Neurología

Figure. Computed tomography axial sequence showing hypodensity in bilateral globus pallidus and posterior limb of internal capsule.; b) Brain T₂-weighted magnetic resonance imaging showing a symmetrical enhancement of both *nuclei pallidus* and posterior limb of internal capsule; c) Diffusion sequence disclosing a blood-brain barrier disruption; d-e) Brain magnetic resonance imaging showing symmetrical areas of necrosis in both *nuclei pallidus*.



scale of 13/15. Cardiovascular, respiratory and abdominal examinations were otherwise unremarkable. On neurological examination, hyporeactive miotic pupils, profuse blinking, marked dysarthria and unstable gait were noted. There were no clinical signs of raised intracranial pressure or meningeal irritation.

Laboratory clinical test results showed hyperchloremic metabolic acidosis (pH: 7.28; actual bicarbonate: 16.4 mmol/L), polyglobulia and macrocytosis. Renal function and hepatic profile were normal. No other findings of interest were found. Toxicological study was negative for ethanol, methanol and ethylene glycol. Urine toxicity screening by immunoassay was positive for benzodiazepines. Computed tomography revealed nonspecific mild symmetrical hypodensities of both *nuclei pallidus* and posterior arms of internal capsules, cerebral atrophy and chronic lacunar infarcts (Figure a).

Suspecting the patient's encephalopathy was related to a pharmacological intoxication (mainly benzodiazepine) without being able to rule out other diagnostic possibilities, he was admitted to the hospital ward. This first hypothesis was supported

by the fact that it was a hypnotic-sedative syndrome in a patient who referred consumption of benzodiazepines and had a positive qualitative study in urine.

Diazepam, nordiazepam and clonazepam plasma levels were requested, all of which were in the therapeutic or infra-therapeutic range (72 ng/mL, 412 ng/mL and negative, respectively). An electroencephalogram showed a diffuse slow activity, without focal or epileptiform abnormalities. Cerebrospinal fluid examination showed mild hyperproteinorachia and all microbiological results were negative.

The anamnesis with the patient was difficult since he provided contradictory information. In this sense, the explanation for which clonazepam levels were negative is that it was not possible to guarantee that the patient had actually taken clonazepam. Given these plasma levels, it is more likely that he had not been taking it. Moreover, the fact that the plasma levels of diazepam and nordiazepam were positive was consistent with the credibility of the information provided by the patient. In retrospect, blisters of diazepam were found in the patient's home. Therapeutic plasma levels do not rule out the possibility of adverse effects, but they make their severity and the clinical course followed by the patient less likely. Benzodiazepines probably contributed to the condition, but causality could not be attributed taking into account these plasma levels.

On the other hand, hyperchloremic acidemia with normal lactate levels in the clinical context of this patient led us to propose the diagnosis of a metabolic disorder, especially organic acidemia, a disorder of fatty acid beta-oxidation, or a disorder of the urea cycle. The systematic study in plasma and urine of fatty acids, acylcarnitines, acylglycines and carnitine was negative. Also, ammonium levels were normal and hypoketotic hypoglycemia was not found. The acidemia resolved in less than 24 hours without any specific measures, which made the hypothesis of a metabolic disorder highly unlikely. Furthermore, during initial stabilization, the patient had received loads of NaCl 0.9%, which could have contributed to acidemia.

Within the following 24 hours, he presented a progressive level of consciousness decrease, with the development of a rapidly progressive respiratory failure that required endotracheal intubation and mechanical ventilation and transfer to the Intensive Care Unit (ICU).

Respiratory examination and thorax X-ray were suggestive of aspiration pneumonia, and he was

treated accordingly. To further study the encephalopathy, a magnetic resonance imaging of the brain was performed (Figure b-c). It revealed extensive bilateral heterogeneous hyperintense signal on fluid-attenuated inversion recovery (FLAIR) and T₂ in both globus pallidus, posterior limb of internal capsule and putamen (Figure b). T₁-weighted sequence showed hypointensity in the mentioned areas.

At this point, the case was reorientated as a disulfiram induced encephalopathy, because the radiologic pattern had been previously reported in the literature in other cases of disulfiram intoxication, as well as in carbon monoxide intoxication. The diagnosis of encephalopathy due to disulfiram was made by exclusion criteria. According to Naranjo et al [5] algorithm with a score of 4 out of 10, it was considered possible to attribute causality to disulfiram in this case. In turn, the published cases of disulfiram encephalopathy present important similarities to the case. There are no reports with inhaled disulfiram since it is not an approved route of administration. Unfortunately, disulfiram plasma could not be performed.

The respiratory condition of the patient gradually improved during the next two weeks making progress in weaning until extubation. After sedatives withdrawal, difficulties of gaze supraversion, intentional tremor and dysmetria in the finger-nose maneuver as well as proximal weakness in upper and lower limbs were noticed on neurological examination. Subsequently, the patient showed neurologic improvement. The ocular motility limitation and weakness were resolved in a few days, but he persisted with mild intentional tremor and slight dysmetria. Due to critically illness myopathy, gait could not examine until two weeks later, when a complete resolution of the ataxia was verified.

The patient was discharged with slight intentional tremor with a scheduled neuroimaging test in two months that showed evolution of symmetrical areas of cytotoxic edema to necrosis (Figure d-e).

Discussion

We report a case of late-onset acute encephalopathy associated to intranasal consume of disulfiram. We have not found previous reports of disulfiram bioavailability or intoxication following this administration route, although high levels have been found experimentally in animals [6]. In our patient the neurotoxicity appeared after many years of treatment, probably due to a massive inhaled intake. Moreover, history of schizophrenia may have contributed to susceptibility to these effects.

In conclusion, disulfiram-induced neurotoxicity must be suspected during chronic therapy with disulfiram or after acute ingestion of high doses, and not necessarily associated with alcohol intake. Symptoms such as symmetric sensory and motor neuropathy, confusion, catatonia, parkinsonism, ataxia, choreoathetosis, seizures and encephalopathy should make us rule out this disorder. A brain imaging test should be performed in these patients since a characteristic involvement of both *nuclei pallidus* has been described, but it is not present in all patients.

References

1. Peddawad D, Nagendra S, Chatterjee R, Faldu H, Chheda A. Fulminant encephalopathy with unusual brain imaging in disulfiram toxicity. *Neurology* 2018; 90: 518-9.
2. Boukriche Y, Weisser I, Aubert P, Masson C. MRI findings in a case of late onset disulfiram-induced neurotoxicity. *J Neurol* 2000; 247: 714-5.
3. Zorzon M, Masè G, Biasutti E, Vitrani B, Cazzato G. Acute encephalopathy and polyneuropathy after disulfiram intoxication. *Alcohol Alcohol* 1995; 30: 629-31.
4. Borrett D, Ashby P, Bilbao J, Carlen P. Reversible, late-onset disulfiram-induced neuropathy and encephalopathy. *Ann Neurol* 1985; 17: 396-9.
5. Naranjo CA, Busto U, Abel JG, Sellers EM. Empirical delineation of the probability spectrum of adverse drug reactions. *Clin Pharmacol Ther* 1981; 29: 267-8.
6. Qu Y, Sun X, Ma L, Li C, Xu Z, Ma W, et al. Therapeutic effect of disulfiram inclusion complex embedded in hydroxypropyl-β-cyclodextrin on intracranial glioma-bearing male rats via intranasal route. *Eur J Pharm Sci* 2021; 156: 105590.

Encefalopatía inducida por disulfiram intranasal: resultados clínicos y de neuroimagen

Introducción. La encefalopatía inducida por disulfiram es una complicación rara que se ha descrito en adultos, generalmente en intoxicaciones agudas, aunque también se ha comunicado en forma de encefalopatía de aparición tardía. Su mecanismo fisiopatológico se desconoce con exactitud, pero se atribuye a un posible papel en la inhibición de la dopamina beta-hidroxilasa mediada por metabolitos tóxicos del disulfiram. El objetivo de este trabajo fue describir los hallazgos clínicos y en la neuroimagen en un caso inusual de encefalopatía aguda tóxica inducida por un consumo intranasal crónico de disulfiram.

Caso clínico. Paciente de 48 años con enolismo crónico que refirió el uso inhalado por vía intranasal de una dosis muy elevada de disulfiram sin ingesta simultánea de alcohol desarrolló una encefalopatía aguda con insuficiencia respiratoria

rápidamente progresiva. La neuroimagen reveló una extensa afectación simétrica bilateral de ambos núcleos pálidos, un hallazgo característico en esta intoxicación. La recuperación neurológica fue lenta. Dos meses después de la intoxicación, el paciente presentaba un ligero temblor intencional residual y una resonancia magnética mostró una evolución de las áreas simétricas de edema citotóxico a necrosis.

Conclusión. La neurotoxicidad inducida por disulfiram debe sospecharse durante el tratamiento crónico con disulfiram o después de una ingesta aguda de dosis elevadas. La presencia de síntomas como una neuropatía sensitivomotora simétrica, confusión, catatonía, parkinsonismo, ataxia, coreoatetosis, convulsiones y encefalopatía nos debe obligar a descartar este trastorno. La neuroimagen debe considerarse en este escenario, ya que se ha descrito una afectación característica de ambos núcleos pálidos.

Palabras clave. Alcoholismo. Disulfiram. Encefalopatía. Infarto del núcleo pálido. Intoxicación. Neurotoxicidad.